

Gastrointestinal and dental morphology of herbivorous mammals: where does the Laotian rock rat fit?

Juha Laakkonen¹, Tuomas Kankaanpää², Ian J. Corfe², Jukka Jernvall²,
Timo Soveri³, Khamsavath Keovichit⁴ & Jean-Pierre Hugot⁵

¹ Department of Veterinary Biosciences, Faculty of Veterinary, Medicine, P.O. Box 66, FI-00014 University of Helsinki, Finland (corresponding author's e-mail: juha.laakkonen@helsinki.fi)

² Institute of Biotechnology, P.O. Box 56, FI-00014 University of Helsinki, Finland

³ Department of Production Animal Medicine, University of Helsinki, Paroninkuja 20, FI-04920 Saarentaus, Finland

⁴ National Agriculture and Forestry Research Institute (NAFRI), Vientiane, Lao Democratic People's Republic

⁵ Département Systématique et Evolution, Muséum National d'Histoire Naturelle, UMR7205 du CNRS55, rue Buffon, FR-75231 Paris cedex 05, France

Received 31 Oct. 2013, final version received 7 Jan. 2014, accepted 13 Jan. 2014

Laakkonen, J., Kankaanpää, T., Corfe, I. J., Jernvall, J., Soveri, T., Keovichit, K. & Hugot, J.-P. 2014: Gastrointestinal and dental morphology of herbivorous mammals: where does the Laotian rock rat fit? — *Ann. Zool. Fennici* 51: 153–161.

We studied dental complexity in *Laonastes aenigmamus* to place this unique rodent species into a comparative context. The complexity of cheek teeth of *Laonastes* are within the range of that for omnivorous mammals feeding predominantly on plants or that for herbivorous mammals. In a comparative sample of predominantly herbivorous hystricomorph rodents, only the degu (*Octodon degus*) and the chinchilla (*Chinchilla chinchilla*) have less complex cheek teeth than *Laonastes*. We also used ethanol fixed stomachs and a silicone cast of stomach of five *Laonastes* to study its macroscopic and microscopic gut anatomy. The stomach of *Laonastes* has four elongated chambers that are partially sacculated. The stomach of *Laonastes* differs microscopically from the typical rodent stomach: most of the epithelium is glandular, and non-glandular stratified squamous epithelium can be found only in the sulcus that is microscopically homogeneous. Microscopic screenings showed that the digesta was similar in all stomach compartments. The mean renal medullary thickness (RMT) in this species is low indicating that its ability to concentrate electrolytes in the urine is low. We discuss the dentition and the stomach morphology of *Laonastes* in relation to observations on its natural diet.

Introduction

Laonastes aenigmamus is the only living species of the Diatomyidae family, otherwise represented by four genera and nine species, all extinct and distributed across Asia and Arabia

from the Early Oligocene to Late Miocene (34–11 Ma) (Dawson *et al.* 2006, Lopez-Antonzas 2011). The geographical distribution of *Laonastes* encompasses only the mountains of Khammouan karst, in the Central Lao People's Democratic Republic (Keovichit *et al.* 2011).

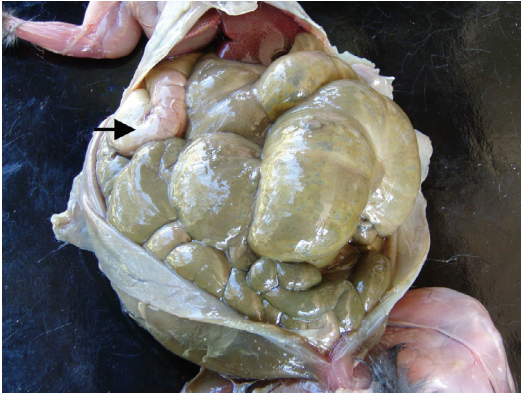

Fig. 1. Ventral overview of the gastrointestinal tract of *Laonastes aenigmamus*. The length of the cavity from the liver (top) to the pelvis is 12 cm. Arrow = *pars pyloric*.

Laonastes postcranial skeleton has been noted to be relatively unremarkable (Jenkins *et al.* 2005, Dawson *et al.* 2006, Huchon *et al.* 2007) but the jaws, masticatory musculature, and dentition are highly distinctive (Jenkins *et al.* 2005, Dawson *et al.* 2006, Hautier *et al.* 2011, Herrel *et al.* 2012). The mandible of *Laonastes* presents an intermediate association of features that could be considered neither sciurognathous nor as hystricognathous (Hautier *et al.* 2011). As compared with fetal crania and musculature, in adult *Laonastes* the rostral part of the skull elongates and the *zygomaticomandibularis* muscle develops disproportionately (Herrel *et al.* 2012).

Dry leaves, especially of Euphorbiaceae form the main part of the diet of *Laonastes*, with additional consumption of structures built by termites and some insects (Jenkins *et al.* 2005, Keovichit *et al.* 2011, J.-P. Hugot pers. obs.). In an analysis of tooth wear indicating the probable diet of the last few meals (Jenkins *et al.* 2005), some differences were reported between individuals. One individual had wear on the teeth suggesting that leaves formed the last meals, while there was evidence of grass and seeds in the diet of a second individual.

Recent studies on the gastrointestinal tract of the Laotian rock rat *Laonastes aenigmamus* (Keovichit *et al.* 2011, Scopin *et al.* 2011) have revealed that these animals appear to digest plant fibre with macroscopically compartmentalized stomachs (Figs. 1 and 2) characterized by a dis-

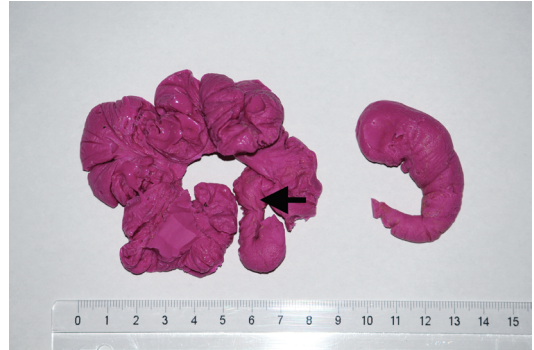

Fig. 2. Silicone cast of the stomach (left) and cecum (right) of *L. aenigmamus* (3M ESP, Express™2, Light Body Standard Quick VPS silicone impression material). Arrow = *pars pyloric*. Dorsal view, scale bar in centimeters.

tinct *sulcus* (Fig. 3). These findings, together with the relatively small body size of *Laonastes* (maximum body weight about 500 grams), beg the question of how the gastrointestinal morphology of *Laonastes* compares to that of other mammals.

Mammal species show remarkable variation in their stomach morphology in terms of compartmentalization and the type of mucosal surface (Barry 1977, Carleton 1973, Langer 2002, Wang *et al.* 2003, Stevens & Hume 2004, Kotze *et al.* 2006). The monogastric compound stomach of the rat (*Rattus norvegicus*) for example, is divided by the *margo plicatus* into the proventricular (non-glandular) and the glandular parts (Baker *et al.* 1979). With an elaborated gastric wall topography, and placement of different types of glandular cells (Abdel-Magied & Taha 2003), even further functional compartmentalization of the mammalian stomach can be achieved.

Different gastrointestinal morphologies are linked to the fermentation of fibrous food components by microbes (Stevens & Hume 1998). Since fermentation takes time, the specialized gut compartments assist the retention of fibrous materials for efficient digestion. There are two broad morphophysiological types of mammalian herbivores that are defined according to whether fermentation takes place in the forestomach cranial to the acid-stomach (as in ruminant and non-ruminant foregut fermenters), or in the hind-gut caudal to the acid-stomach (as in colon and cecum fermenters, Stevens & Hume 1998). Each of these systems have their own benefits and

drawbacks with regard to digestive efficiency, but for both types of herbivore, body size is thought to be a key factor in their ecology and evolution through its impacts of energy/nutrients requirements and gut capacity (Demment & Van Soest 1985, Müller *et al.* 2013).

Many small mammalian herbivores minimize faecal protein losses (in the form of bacterial matter) by selectively collecting bacteria in their hindgut by special retention mechanisms (Hume & Sakaguchi 1991), excreting these in a controlled fashion (e.g., by distinctively formed, special faeces) and re-ingesting them (Franz *et al.* 2011). Clauss *et al.* (2007a) suggested that coprophagy may be assumed per default in any herbivorous rodent unless proven otherwise.

Although we described the general characteristics of *Laonastes* morphology above, our purpose was to further investigate *Laonastes* stomach characteristics as well as quantify functional aspects of dental form for comparison to other rodent species. We also aimed to compare the known morphology of this species to our behavioral observations on captive *Laonastes* individuals.

Since an important aspect of the gastric function is the physical separation of constituents of digesta (Langer 1984, Munn *et al.* 2012), we screened the stomach chambers of *Laonastes* to see whether there is any significant retention of coarse particles in the cranial stomach chambers. We also examined the stomach microanatomy of *Laonastes*, and used behavioral observations in an effort to find direct evidence that *Laonastes* is coprophagous.

Finally, since the diet of *Laonastes* consists mainly of dry items, we studied the ability of this species to concentrate electrolytes in its urine (Schmidt-Nielsen & O'Dell 1961), and compared this with the corresponding ability in other mammalian species in order to obtain an estimation on how well *Laonastes* is adapted to dry environments.

Material and methods

Laonastes aenigmamus has been protected in Laos since 2008, and it has been on the International Union for Conservation of Nature (IUCN) Red list since 2009. The Lao authorities have

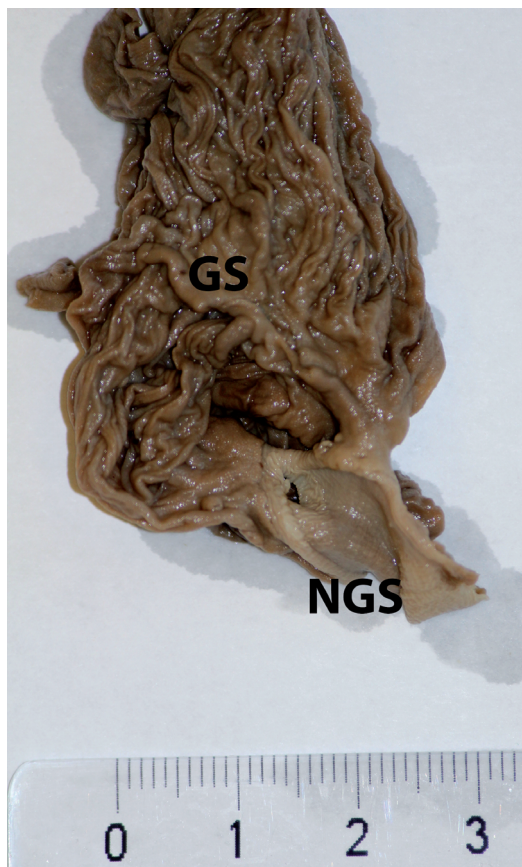


Fig. 3. The non-glandular sulcus (NGS) is distinctly visible against the darker glandular part (GS) of the *Laonastes* stomach. Ethanol fixed specimen. Scale bar in centimeters.

taken the responsibility to inform local human populations of this new legislation (*Laonastes* was trapped locally for food). During the transitional period the capture of this species was tolerated to allow its scientific study. With an exceptional letter of authorization (no. 1183, 9 June 2008) obtained from the Lao Government (Ministry of Planning and Investment), we were able to acquire five adult specimens (found dead in local hunters' traps in the Khammouane Province) which provided us with some additional information on the teeth and gastrointestinal morphology of *Laonastes*. We also had access to some additional skulls from earlier studies for teeth analyses.

On necropsy, we placed the entire gastrointestinal tracts in ethanol for later studies done

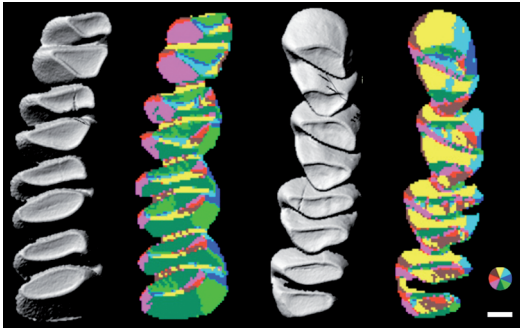


Fig. 4. Three-dimensional occlusal reconstructions of *Laonastes* lower-right (left) and upper-right (right) cheek tooth rows for GIS analysis. The colored versions of the tooth rows show surface orientation maps of three-dimensional reconstructions (color wheel indicates orientation). The mean number of patches (OPC) are 182 for the lower and 152 for the upper tooth row (using the entire cheek tooth row and 150 pixel resolution). Anterior is towards the top. Scale bar = 1 mm.

in laboratory in Finland. Additionally, skulls ($n = 9$) were cleaned and also shipped to Finland for analyses of the teeth. In order to quantify the dental form, we measured three-dimensional dental complexity of *Laonastes aenigmamus* cheek tooth rows using geographic information systems (GIS) analysis (for details see Evans *et al.* 2007: fig. 4). This method, termed Orientation Patch Count (OPC), and which measures the number and orientation of patches on tooth crown surfaces, does not require tooth feature homologies to be established, and approximates the number of tools on the tooth that can break down food material (Evans *et al.* 2007). It has been previously shown to provide estimations of diet in rodents, carnivores, primates, and bats (Evans *et al.* 2007, Santana *et al.* 2011, Godfrey *et al.* 2012), and used to infer the diet of extinct mammalian taxa such as multituberculates, and plesiadapid and lemuriform primates (Boyer *et al.* 2010, Godfrey *et al.* 2012, Wilson *et al.* 2012). Because OPC has previously been determined for murine rodents, we additionally scanned and analyzed a selection of hystricomorph rodents. Three-dimensional laser scans were obtained and processed as previously described (Evans *et al.* 2007, Wilson *et al.* 2012).

We microscopically screened ethanol fixed stomach chambers of *Laonastes* in an effort to see if there was physical separation of particles

of different sizes in different stomach compartments. Standard histological sections ($5 \mu\text{m}$) were prepared from each of the stomach chambers of *Laonastes*, and stained with Hematoxylin-eosin. Sections were studied by microscope at $200\times$ magnification. Here our aim was to determine how the glandular and non-glandular sections of the stomach were located.

In an effort to estimate how well *Laonastes* concentrates electrolytes in its urine, we measured the renal medullary thickness (RMT, Sperber 1944) of two *Laonastes* specimens as described in Laakkonen (2002). Behavioral data were gathered by observing captive *Laonastes* (Keovichit *et al.* 2011). Anatomical terminology is in accordance with the International Committee on Veterinary Cross Anatomical Nomenclature (2012).

Results

Teeth

The Orientation Patch Count for *Laonastes* cheek tooth (Fig. 4 and Table 1) rows corresponds to the OPC range of taxa among murine that are omnivorous but feed predominantly on plant-dominated diet or are strictly herbivorous (Evans *et al.* 2007). The OPC values peak in adult *Laonastes* individuals as compared with those in juvenile and senescent specimens (Table 1), and, at least for lower toothrows, adult mean OPC (lower toothrow = 206, upper toothrow = 155) falls within the herbivory category of Evans *et al.* (2007). In contrast to nearly all murine and hystricomorph rodents analyzed to date, the lower toothrow of *Laonastes* appears to have higher OPC values than the upper toothrow.

Stomach anatomy

Our histological examination of the stomach anatomy of *Laonastes* showed that each of the stomach chambers of *Laonastes* (not shown) is microscopically similar, consisting of glandular (simple columnar) epithelium. A gastric sulcus (*sulcus ventriculi*) runs along the stomach wall at the lesser curvature (*curvature ventriculi minor*)

from the oesophagus towards the pylorus, ending shortly before the latter (Scopin *et al.* 2011: fig. 3). The gastric sulcus (*sulcus ventriculi*) is lined by macroscopically and microscopically visible low folds of tissue (bordering fold in the terminology of Carleton 1973) separating the sulcus from the glandular part of the stomach. Microscopically the sulcus was similar throughout its length in adult *Laonastes* consisting of stratified squamous epithelium. At the caudal part of the stomach *Laonastes* has a well-developed pyloric sphincter muscle (not shown).

In microscopic screenings of food particles from various ethanol fixed stomach chambers of *Laonastes*, we saw no significant differences in digesta particle size patterns between different stomach regions. We saw no sign of *Laonastes* eating their own feces but we frequently saw

them licking their perianal areas (J.-P. Hugot pers. obs.).

The RMTs of *Laonastes* were 3.18 and 4.24 (mean 3.71).

Discussion

Placing the dentition into a broad comparative context, the bilophodonty of *Laonastes* cheek teeth is not in itself indicative of extreme specialization for plant fibre consumption. The teeth, however, are mesodont and cusps are somewhat lamellar (Fig. 4), features that suggest increased functional durability and functional efficiency, respectively (Janis & Fortelius 1988).

The number of patches or dental complexity (OPC value) recorded for a cheek tooth row

Table 1. Tooth row complexity (OPC) of different-aged *Laonastes* (age categories are based on tooth wear), selected hystricomorph rodents (adults), and carnivorans and rodents (murines and sigmodontines) with predominantly herbivorous diets (data from Evans *et al.* 2007). Values are for the whole cheek tooth row and the three molars only (in parentheses). The OPC values are calculated using 150 pixel data rows for the entire cheek tooth row and the three molars. Diet information from Meserve *et al.* (1984), Emmons (1997), Dubost and Henry (2006), Townsend and Croft (2008), Coltrane and Barboza (2010). *Laonastes* specimens are from National Museum of Natural History, Paris, and the other specimens from the Finnish Museum of Natural History, Helsinki. For details on the corresponding data see Evans *et al.* (2007).

Species	Specimen ID	OPC of lower teeth	OPC of upper teeth	Diet
Carnivores ($n = 2$)	See Evans <i>et al.</i> (2007)	179–192	150–170	Plant dominated omnivory
Carnivores ($n = 2$)	See Evans <i>et al.</i> (2007)	195–257	270–342	Herbivory
Rodents ($n = 33$)	See Evans <i>et al.</i> (2007)	133–287	162–309	Plant dominated omnivory
Rodents ($n = 5$)	See Evans <i>et al.</i> (2007)	189–277	196–309	Herbivory
<i>Octodon degus</i>	UN2285	136 (161)	143 (142)	Grass and shrub foliage, seeds
<i>Chinchilla chinchilla</i>	UN2288	136 (152)	157 (200)	Mostly grasses
<i>Lagostomus maximus</i>	UN2291	201 (218)	304 (318)	Mostly grasses
<i>Myocastor coypus</i>	UN2292	226 (241)	349 (371)	Grasses, sedges, roots
<i>Dasyprocta leporine</i>	UN2287	228 (265)	265 (300)	Fruits, nuts, seeds, insects
<i>Cavia porcellus</i>	UN2286	230 (271)	205 (222)	Mostly grasses
<i>Erethizon dorsatum</i>	UN2290	272 (288)	330 (251)	Generalist herbivore
<i>Cuniculus paca</i>	3/1960	294 (291)	330 (381)	Fruits, nuts, seeds, leaves, tubers
<i>Laonastes aenigmamus</i>	91 (juvenile, m3 partially erupted)	162 (164)	146 (148)	Dry leaves, some insects
<i>Laonastes aenigmamus</i>	75 (juvenile)	186 (205)	155 (178)	Dry leaves, some insects
<i>Laonastes aenigmamus</i>	114 (juvenile)	154 (166)	142 (141)	Dry leaves, some insects
<i>Laonastes aenigmamus</i>	113 (adult)	187 (202)	147 (202)	Dry leaves, some insects
<i>Laonastes aenigmamus</i>	78 (adult)	231 (254)	140 (167)	Dry leaves, some insects
<i>Laonastes aenigmamus</i>	86 (adult)	200 (206)	177 (215)	Dry leaves, some insects
<i>Laonastes aenigmamus</i>	108 (old)	166 (177)	158 (225)	Dry leaves, some insects
<i>Laonastes aenigmamus</i>	120 (old)	179 (192)	155 (177)	Dry leaves, some insects
<i>Laonastes aenigmamus</i>	73 (old)	173 (159)	152 (206)	Dry leaves, some insects

increases with increasingly fibrous diets, from a low count in hypercarnivores, increasing through carnivory, animal-dominated omnivory and plant-dominated omnivory, and with the highest values recorded for fibre specialists such as the bamboo-eating giant panda, *Ailuropoda melanoleuca*. The value for *Laonastes* cheek tooth rows corresponds to the OPC range of predominantly herbivorous taxa among those mammalian species examined previously (Fig. 4), agreeing with the field observations (J.-P. Hugot pers. obs.). Furthermore, OPC values of *Laonastes* are lower than those of the most specialized hindgut fermenting herbivores analyzed by Evans *et al.* (2007), and could implicate the role of its compartmentalized stomach in the digestion of high fibre content plant material. Comparison with hystricomorphs, however, shows that *Laonastes* OPC values are well within the range of these herbivorous grass eaters (Table 1). It is perhaps noteworthy that *Octodon* and *Chinchilla*, which are specialized in eating dry and high-fibre-content plants, have even lower OPC values than *Laonastes*. *Octodon* and *Chinchilla* are also coprophagous but currently it is not known whether dental form is affected by coprophagy.

Laonastes has a voluminous stomach characterized by sacculations (Keovichit *et al.* 2011, Scopin *et al.* 2011; Figs. 1 and 2) partly resulting from the constriction caused by the strong peritoneal folds originating in the lesser curvature. This kind of stomach morphology, called by Langer (1985) plurilocular (multichambered), provides the capacity to hold a portion of the digesta for long periods of time for thorough microbial digestion. In this study, we found no significant differences in digesta particle size patterns between different stomach regions. Jenkins *et al.* (2005) reported that the stomach contents consisted mainly of very fine particulate matter (plant remains). In other mammal species with multichambered stomachs, a differential passage of solute and particles has been documented in hippopotamus (Clauss *et al.* 2004), macropods (Munn *et al.* 2012) and functional ruminants (ruminants and camelids, reviewed in Müller *et al.* 2011), but apart from ruminants and camelids, no differential passage of different-sized particles (Schwarm *et al.* 2009, Munn *et al.* 2012) or systematic differences in particles sizes

in the different forestomach compartments has been identified (Schwarm *et al.* 2013).

The stomach chambers of *Laonastes* all appeared microscopically similar, consisting of glandular (simple columnar) epithelium. Since the *Laonastes* used in this study were found dead in traps, the stomach epithelium had started to dissolve and was not in optimum condition for histological examination. Stomach specimens collected and fixed immediately after the death of an individual would be needed to study the microanatomy of *Laonastes* in more detail.

Non-ruminating mammals with large stomachs show variability in the microanatomy of their stomachs. In macropods, the foregut contains regions of squamous epithelium and cardiac glandular mucosa (Smith 2009), and in the pigmy hippopotamus the walls of the forestomach are covered with villi and a non-glandular mucous membrane (Macdonald & Hartman 1983).

Of other rodent species, several African rodent species have markedly sacculated stomachs and a conspicuous folded edge of the mucous membrane separating the highly modified corpus (numerous papillae or several diverticula) from a glandular antrum (Perrin & Maddock 1983). Of these species, *Thallomys paedulus* is a specialist folivore feeding on fibrous leaves. It has an elaborate oesophageal groove system and fornical diverticula (Perrin & Maddock 1983). None of these African rodent species has a stomach sulcus similar to that of *Laonastes*. The microanatomy of *Laonastes* stomach appears dissimilar from that of any other rodent or mammal species.

Microscopically the sulcus of *Laonastes* was similar throughout its length in adult *Laonastes* and consisted of stratified squamous epithelium. As in other mammals that have a stomach sulcus, also in *Laonastes* this groove like structure may be an adaptation to easily bypass milk in juveniles straight to the caudal part of the stomach. A study done in ruminants indicates that it is unlikely that even soluble food components are bypassed in such a structure (Lechner *et al.* 2009). *Laonastes* have been observed to occasionally chew while resting (J.-P. Hugot pers. obs.). Whether this is indicative of a regurgitation/remastication behaviour remains to be investigated.

Due to the competition of internal organs for the available space within the abdominal cavity, the large size of the stomach usually limits the size of the cecum and colon (for example in hippopotamus Stevens and Hume 2004), which decreases the ability for colonic water absorption. Despite the large stomach, *Laonastes* has a distinct although undifferentiated cecum (Scopin *et al.* 2011) that may be needed to compensate for the possible lack of fermentation in the non-glandular stomach.

The low RMT (mean = 3.71) indicates that *Laonastes* is not particularly well adapted to dry environments (Al-kahtani *et al.* 2004), and has to rely on habitat choice and behavioral adaptations to survive the dry season. Captive *Laonastes* seldom use water made available for them but can consume moist food items (fruits) without apparent diarrhea or change in the consistency of fecal droppings (J.-P. Hugot pers. obs.). However, this species has been observed to rapidly ingest dry leaves after a period in captivity with only softer food items made available (J.-P. Hugot pers. obs.).

At present, there is no direct evidence that *Laonastes* is coprophagous but this species has frequently been observed to lick their perianal areas (J.-P. Hugot pers. obs.). Whether this behavior is part of the process of ingesting feces, as documented in other coprophageous species (e.g. Kenagy & Hoyt 1980), is presently not known.

Large body size has often been suggested to make the use of food items high in crude fibre content (such as plant cell walls) easier due to the lower relative energy requirements of large mammals as compared to those of mammals with small body size. Recent studies suggest however, that in herbivores the difference could be less marked than predicted simply on the basis of the body size-metabolic rate relationship (Müller *et al.* 2013). Instead, interactions between food intake and food residence time may be more important for understanding the evolution and ecology of herbivores (Clauss *et al.* 2007b).

The combination of relatively complex teeth, unique gut morphology and relatively small body size of *Laonastes* provide intriguing possibilities for further studies on the relation of body size,

diet choice and gastrointestinal morphophysiology in herbivorous mammals.

Acknowledgements

We would like to thank Dr. Bounthong Bouahom, Director of the National, Agricultural and Research Institute (NAFRI) for his gracious support and interest for our investigative efforts. We also thank M. Phomma Phanthalangsy, Director of the Provincial Agriculture and Forestry Office (PAFO) of the Khammouan Province, and the officers of the districts of Hinboun, Takhek, Gnomalath and Mahaxai for their generous help with the fieldwork. Finally, we want to thank the Nam Theun 2 Power Company (Vientiane, Lao PDR) for its logistical help during field investigations, and particularly M. Aiden Glendinning and M. Olay Phommavong. Our research received financial support from the Franco-Lao program, "Biology, Ecology and Genetics of *Laonastes aenigmamus* living fossil in the Lao PDR," in cooperation with the Lao PDR Ministry of Agriculture (J-PH) and from the Academy of Finland (JJ).

References

- Abdel-Magied, E. M. & Taha, A. A. 2003: Morphological, morphometric and histochemical characterization of the gastric mucosa of the camel (*Camelus dromedarius*). — *Anat. Hist. Embryol.* 32: 42–47.
- Al-kahtani, M. A., Zuleta, C., Caviedes-Vidal, E. & Garland, T. Jr. 2004: Kidney mass and relative medullary thickness of rodents in relation to habitat, body size, and physiology. — *Physiol. Biochem. Zool.* 77: 346–365.
- Baker, H. J., Lindsey, J. R. & Weisroth, S. H. 1979: *The laboratory rat*, vol. 1. *Biology and diseases*. — Academic press Inc., Orlando, FL.
- Barry, R. E. Jr. 1977: Length and absorptive surface area apportionment of segments of the hindgut for eight species of small mammals. — *J. Mammal.* 58: 419–420.
- Boyer, D. M., Evans, A. R. & Jernvall, J. 2010: Evidence of dietary differentiation among late Paleocene–early Eocene plesiadapids (Mammalia, Primates). — *Am. J. Phys. Anthropol.* 142: 194–210.
- Carleton, M. D. 1973: *A survey of gross stomach morphology in New World Cricetinae (Rodentia, Muroidea), with comments on functional interpretations*. — Miscellaneous Publications no. 48, Museum of Zoology, University of Michigan, USA.
- Clauss, M., Schwarm, A., Ortman, S., Alber, D., Flach, E. J., Kühne, R., Hummel, J., Streich, W. J. & Hofer, H. 2004: Intake, ingesta retention, particle size distribution and digestability in the hippopotamidae. — *Comp. Biochem. Physiol. A* 139: 449–459.
- Clauss, M., Besselmann, D., Schwarm, A., Ortman, S. & Hatt, J.-M. 2007a: Demonstrating coprophagy with passage markers? The example of the plains viscacha (*Lagostomus maximus*). — *Comp. Biochem. Physiol. A*

- 147: 453–459.
- Clauss, M., Schwarm, A., Ortmann, S. & Streich, W. J. & Hummel, J. 2007b: A case of non-scaling in mammalian physiology? Body size, digestive capacity, food intake, and ingesta passage in mammalian herbivores. — *Comp. Biochem. Physiol. A* 148: 249–265.
- Coltrane, J. A. & Barboza, P. S. 2010: Winter as a nutritional bottleneck for North American porcupines (*Erethizon dorsatum*). — *J. Comp. Physiol. B* 180: 905–918.
- Dawson, M. R., Marivaux, L., Li, C. K., Beard, C. & Métais, G. 2006: *Laonastes* and the “Lazarus” effect in recent mammals. — *Science* 311: 1456–1458.
- Demment, M. W. & Van Soest, P. J. 1985: A nutritional explanation for body-size patterns of ruminant and non-ruminant herbivores. — *Am. Nat.* 125: 641–672.
- Dubost, G. & Henry, O. 2006: Comparison of diets of the acouchy, agouti and paca, the three largest terrestrial rodents of French Guianan forests. — *J. Tropical Ecol.* 22: 641–651.
- Emmons, L. H. 1997: *Neotropical rainforest mammals: a field guide* — The University of Chicago Press, Chicago.
- Evans, A. R., Wilson, G. P., Fortelius, M. & Jernvall, J. 2007: High-level similarity of dentitions in carnivores and rodents. — *Nature* 445: 78–81.
- Franz, R., Kreuzer, M., Hummel, J., Hatt, J.-M. & Clauss, M. 2011: Intake, selection, digesta retention, digestion and gut fill of two coprophageous species, rabbits (*Oryctolagus cuniculus*) and guinea pigs (*Cavia porcellus*), on a hay-only diet. — *J. Anim. Physiol. Anim. Nutr.* 95: 564–570.
- Godfrey, L. R., Winchester, J. M., King, S. J., Boyer, D. M. & Jernvall, J. 2012: Dental topography indicates ecological contraction of lemur communities. — *Am. J. Phys. Anthropol.* 148: 215–227.
- Hautier, L., Lebrun, R., Saksiri, S., Michaux, J., Vianey-Liaud, M. & Marivaux, L. 2011: Hystricognathy vs sciurognathy in the rodent jaw: a new morphometric assessment of hystricognathy applied to the living fossil *Laonastes* (Diatomyidae). — *PLoS ONE* 6(4): e18698, doi:10.1371/journal.pone.0018698.
- Herrel, A., Fabre, A. C., Hugot, J. P., Keovichit, K., Adriaens, D., Brabant, L., Van Hoorbeke, L. & Cornette, R. 2012: Ontogeny of the cranial system in *Laonastes aenigmamus*. — *J. Anat.* 221: 128–137.
- Huchon, D., Chevret, P., Jordan, U., Kilpatrick, C. W., Ranwez, V., Jenkins, P. D., Brosius, J. & Schmitz, J. 2007: Multiple molecular evidences for a living mammalian fossil. *PNAS* 104: 7495–7499.
- Hume, I. D., Sakaguchi, E. 1991: Patterns of digesta flow and digestion in foregut and hindgut fermenters. — In: Tsuda, T., Saaski, Y. & Kawashima, R. (eds.), *Physiological aspects of digestion and metabolism in ruminant*: 427–451. Academic Press, San Diego.
- International Committee on Veterinary Gross Anatomical Nomenclature 2012: *Nomina Anatomica Veterinaria*, 5th ed. — The Editorial Committee Hannover (Germany), Columbia, MO (U.S.A.), Ghent (Belgium), Sapporo (Japan).
- Janis, C. M. & Fortelius, M. 1988: On the means whereby mammals achieve increased functional durability of their dentitions, with special reference to limiting factors. — *Biol. Rev.* 63: 197–230.
- Jenkins, P. D., Kilpatrick, C. W., Robinson, M. F. & Timmins, R. J. 2005: Morphological and molecular investigations of a new family, genus and species of rodent (Mammalia: Rodentia: Hystricognatha) from Lao PDR. — *Syst. Biodivers.* 2: 419–454.
- Kenagy, G. J. & Hoyt, D. F. 1980: Reingestion of feces in rodents and its daily rhythmicity. — *Oecologia* 44: 403–409.
- Keovichit, K., Nicolas, V. & Hugot, J.-P. 2011: *Laonastes aenigmamus*, an enigmatic rodent recently discovered in Laos. — *Bull. Acad. Vét. France* 164: 143–148. [In French with an English summary].
- Kotze, S. H., Van Der Merwe, E. L. & O’Riain, M. J. 2006: The topography and gross anatomy of the gastrointestinal tract of the Cape dune mole-rat (*Bathyergus suillus*). — *Anat. Histol. Embryol.* 35: 259–264.
- Laakkonen, J. 2002: Relative medullary thickness of shrews from arid environments: intraspecific spatial analysis, and comparison to arctic shrews and tropical tenrecs. — *Ann. Zool. Fennici* 39: 249–255.
- Langer, P. 1984: Comparative anatomy of the stomach in mammalian herbivores. — *Quart. J. Exp. Physiol.* 69: 615–625.
- Langer, P. 1985: The mammalian stomach: structure, diversity and nomenclature. — *Acta Zool. Fennica* 170: 99–102.
- Langer, P. 2002: The digestive tract and life history of small mammals. — *Mammal Rev.* 32: 107–131.
- Lechner, I., Barboza, P., Collins, W., Günther, D., Hattendorf, B., Hummel, J. & Clauss, M. 2009: No ‘bypass’ in adult ruminants: passage of fluid ingested vs. fluid inserted into the rumen in fistulated muskoxen (*Ovibos moschatus*), reindeer (*Rangifer tarandus*) and moose (*Alces alces*). — *Comp. Biochem. Physiol. A* 154: 151–156.
- López-Antoñanzas, R. 2011: First diatomyid rodent from the Early Miocene of Arabia. — *Naturwissenschaften* 98: 117–123.
- Macdonald, A. A. & Hartman, W. 1983: Comparative and functional morphology of the stomach in the adult and newborn pigmy hippopotamus (*Choeropsis liberiensis*). — *J. Morphol.* 177: 269–276.
- Meserve, P. L., Martin, R. E. & Rodriguez, J. 1984: Comparative ecology of the caviomorph rodent *Octodon degus* in two Chilean Mediterranean-type communities. — *Revista Chilena de Historia Natural* 57: 79–89.
- Munn, A. J., Tomlinson, S., Savage, T. & Clauss, M. 2012: Retention of different-sized particles and derived gut fill estimate in tammar wallabies (*Macropus eugenii*): Physiological and methodological considerations. — *Comp. Biochem. Physiol. A* 161: 243–249.
- Müller, D. W. H., Caton, J., Codron, D., Schwarm, A., Lentle, R., Streich, W. J., Hummel, J. & Clauss, M. 2011: Phylogenetic constraints on digesta separation: variation in fluid throughput in the digestive tract in mammalian herbivores. — *Comp. Biochem. Physiol. A* 160: 207–220.
- Müller, D. W. H., Codron, D., Meloro, C., Munn, A., Schwarm, A., Hummel, J. & Clauss, M. 2013: Assessing

- the Jarman-Bell Principle: scaling of intake, digestibility, retention time and gut fill with body mass in mammalian herbivores. — *Comp. Biochem. Physiol. A* 164: 129–140.
- Perrin, M. R. & Maddock, A. H. 1983: Anatomical and nutritional adaptations in African rodents. — *S. Afr. J. Anim. Sci.* 13: 23–25.
- Santana, S. E., Strait, S. & Dumont, E. R. 2011: The better to eat you with: functional correlates of tooth structure in bats. — *Funct. Ecol.* 25: 839–847.
- Schmidt-Nielsen, B. & O'Dell, R. 1961: Structure and concentrating mechanism in the mammalian kidney. — *Am. J. Physiol.* 200: 1119–1124.
- Schwarm, A., Ortmann, S., Wolf, C., Streich, W. J. & Clauss, M. 2009: Passage marker excretion in red kangaroo (*Macropus rufus*), collared peccary (*Pecari tajacu*) and colobine monkeys (*Colobus angolensis*, *C. polykomos*, *Trachypithecus johnii*). — *J. Exp. Zool. A* 311: 647–661.
- Schwarm, A., Ortmann, S., Fritz, J., Rietschel, W., Flach, E. J. & Clauss, M. 2013: No distinct stratification of ingesta particles and no distinct moisture gradient in the forestomach of nonruminants: the wallaby, peccary, hippopotamus, and sloth. — *Mammal Biol.* 78: 412–421.
- Scopin, A. E., Saveljev, A. P., Suntsova, N. A., Gnophanxay, S., Tikhonov, A. N. & Abramov A. V. 2011: Digestive system of the Laotian rock rat *Laonastes aenigmamus* (Rodentia: Diatomyidae) from the evolutionary viewpoint. — *Proc. Zool. Inst. RAS* 315: 3–18.
- Smith, J. A. 2009: Macropod nutrition. Veterinary clinics of North America. — *Exot. Anim. Pract.* 12: 197–208.
- Sperber, I. 1944: Studies on the mammalian kidney. — *Zool. Bidrag från Uppsala* 22: 249–432.
- Stevens, C. E. & Hume, I. D. 1998: Contributions of microbes in vertebrate gastrointestinal tract to production and conservation of nutrients. — *Physiol. Rev* 78: 393–427.
- Stevens, C. E. & Hume, I. D. 2004: *Comparative physiology of the vertebrate digestive system*. — Cambridge University Press, Cambridge, UK.
- Townsend, K. E. B. & Croft, D. A. 2008: Enamel microwear in caviomorph rodents. — *J. Mammal.* 89: 730–743.
- Wang, D.-H., Pei, Y.-X., Yang, J.-C. & Wang, Z.-W. 2003: Digestive tract morphology and food habits in six species of rodents. — *Folia Zool.* 52: 51–55.
- Wilson, G. P., Evans, A. R., Corfe, I. J., Smits, P. D., Fortelius, M. & Jernvall, J. 2012: Adaptive radiation of multituberculate mammals before the extinction of dinosaurs. — *Nature* 483: 457–460.